



TELECYTOLOGY

## Specialty Services

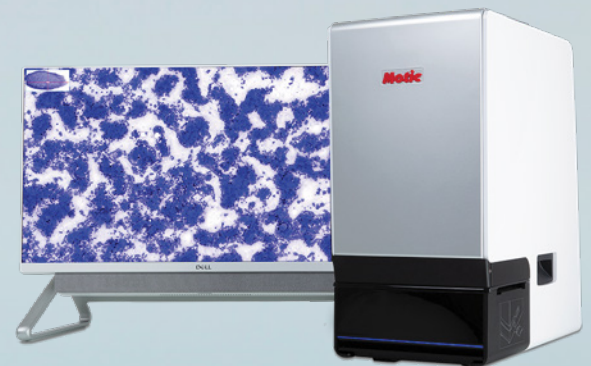
Clinical Pathology in your practice... on demand! Wield the power of digital telecytology with board certified clinical pathologists across the globe.

Comprehensive reports in minutes

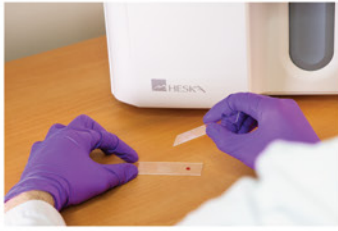STAT service

Real-time chat support

Board-certified clinical pathologists



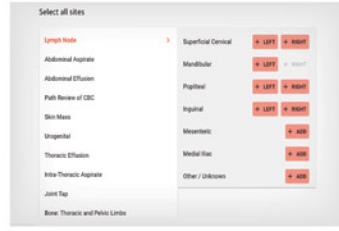
## Easy Operation



1 Obtain sample.  
Stain with Diff Quik



2 Place prepared slide into scanner



3 Enter patient and site information



Pathologist review and report

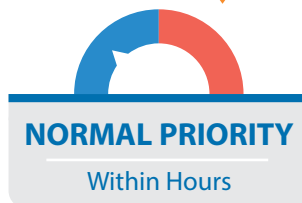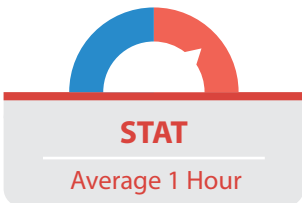
## The HESKAView Telecytology™ Advantage

Provide better diagnosis and treatment for difficult or time-consuming cases.

- Elevate standard of patient care
- Expedite client communication
- Eliminate delays in slide review
- Move on to next step diagnostics and treatment same day



## Turn-around time priorities...



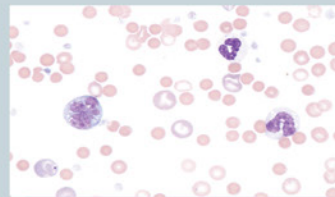
## Add a specialty service to your practice without hiring a specialist!

Digital telecytology allows timely access to veterinary clinical pathologists who can assist with diagnostic evaluation of your patients. Choose STAT\* or Normal Priority<sup>§</sup> turn-around time options. Whether you are a cytology novice or expert, the board-certified pathologists at HESKAView Specialty Services can help with everything from blood smears to fine needle aspirates to pre-surgical planning and more.

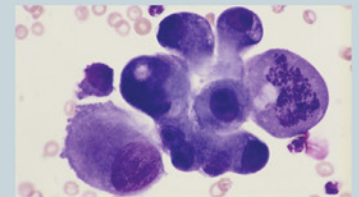
### Examples of Submissions

- CBC Pathology Review
- Dermal & Subcutaneous Masses
- Lymph Nodes
- Body Cavity Effusions
- Joint Taps
- Oral & Nasal Masses
- Abdominal Organs & Masses
- Thoracic Organs & Masses
- BAL/TTW
- Urogenital Cytology
- Vaginal Cytology
- Bone Lesions
- Bone Marrow Cytology
- CSF Cytology and more...

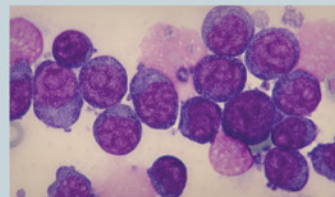
## Get answers to difficult and time-consuming cases



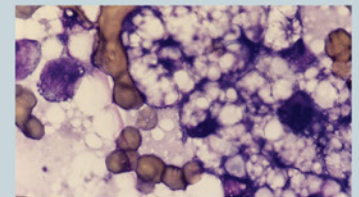
**Image source:** 4 year old M/C Cocker Spaniel; peripheral blood film: **Immune mediated hemolytic anemia?**




**Image source:** 12 year old F/S cat: 1.5 cm diameter mass near the angle of the jaw: **Cancer or inflammation?**



**Image source:** 6 year old M/C GSD: 3.5 cm soft mass in submandibular: **Lymphadenitis, lymphoma or a sialocele?**



**Image source:** 8 year old F/S cat: hepatomegaly and increased liver enzymes: **Hepatic lipidosis or cancer?**



www.heskavet.ca +1.866.382.6937

\*For preliminary interpretation. Additional STAT charges apply. <sup>§</sup>Average turnaround times may vary. Longer turnaround times may be experienced during peak submission times, overnights and on weekends. ©2024 HESKA Corporation. All Rights Reserved. Antech, the Antech logo, and all other trademarks used herein are the registered trademarks of Antech Diagnostics, Inc. or its affiliates. Specifications and appearance may be changed without notice. Motic is a registered trademark of Motic Instruments Inc. HESKA is a registered trademark and HESKAView Telecytology is a trademark of HESKA Corporation in the United States and in other countries. CA21LT0308\_002

**HESKA**  
AN ANTECH® COMPANY